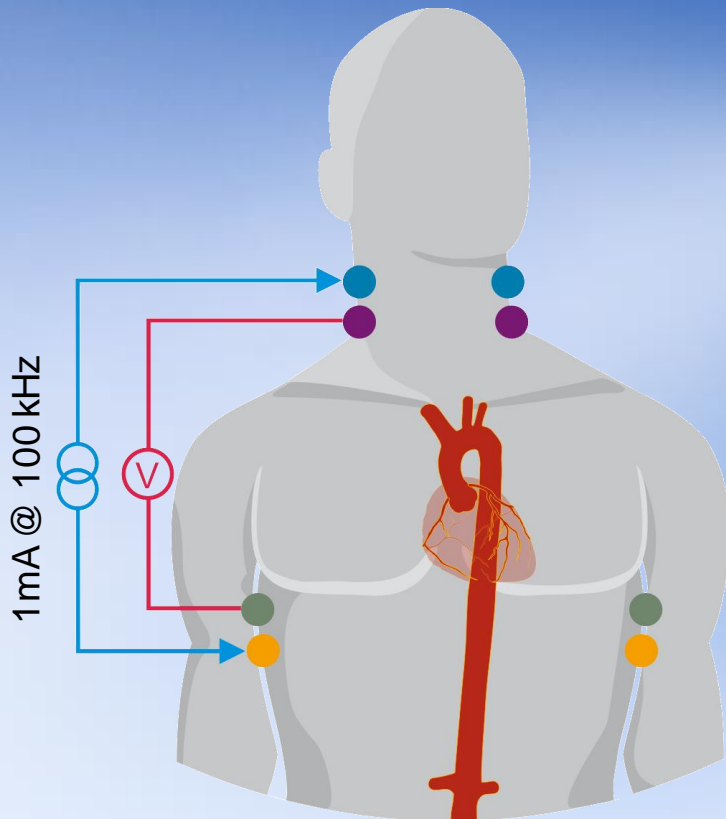


Impedance Cardiography (ICG)

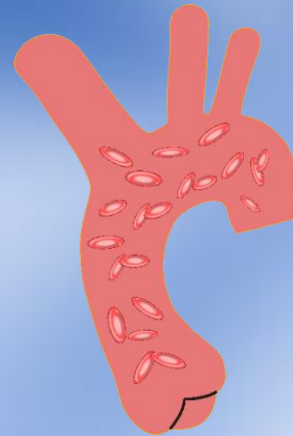
Application of ICG for Hypertension Management

Impedance Cardiography (ICG)

Non-invasive Beat-to-beat Hemodynamic Monitoring

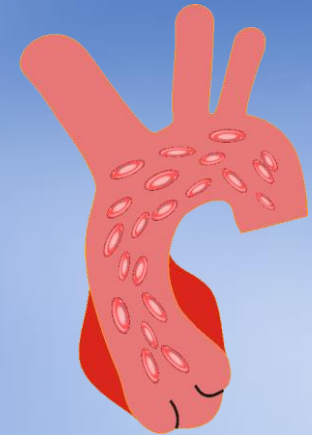


Diastole



- Aortic valve is closed
- No blood flow in the aorta
- Red blood cells are orientated randomly

Systole



- Aortic valve opens
- Blood flow in the aorta (Windkessel function)
- Alignment of red blood cells



Sources of the measured impedance change

Impedance Cardiography (ICG)


ACM – Arterial Compliance Modulation Latest Technology in ICG

Earlobe sensor:

- Registration of peripheral pulse wave
- Calculation of aortic compliance based on pulse wave velocity and curve shape parameters
- Completion to standard ICG measurement to improve parameter calculation

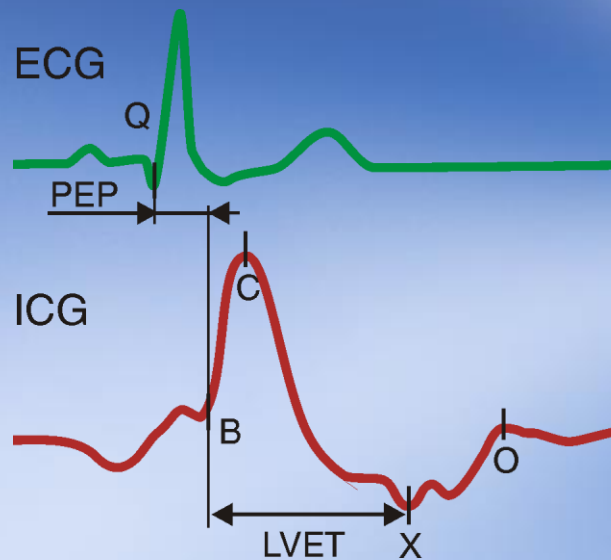
▶ Patient related arterial stiffness

ACM
arterial compliance modulation



Impedance Cardiography (ICG)

ICG waveform and fiducial points



A-wave	-	Contraction of atrium
B	-	Opening of aortic valve
C	-	Max. systolic flow
X	-	Closing of aortic valve
Y	-	Closing of pulmonic valve
O	-	Opening of mitral valve
PEP	-	Pre-Ejection Period
LVET	-	Left Ventricular Ejection Time

- Automatic detection of fiducial points
- Calculation of hemodynamic parameters (e.g. Stroke Volume [SV], Cardiac Output [CO], Thoracic Fluid Content [TFC])

Impedance Cardiography (ICG)

Equation for Stroke Volume Estimation

$$SV = V_{EPT} \cdot \frac{dZ_{\max}}{Z_0} \cdot LVET$$

SV	Stroke Volume
V_{EPT}	Patient related parameter (depending on age, weight, height, gender, ACM etc.)
dZ_{\max}	Amplitude of the systolic wave of the ICG
Z_0	Base impedance (overall impedance of the thorax)
LVET	Left Ventricular Ejection Time: time interval between opening and closing of the aortic valve

Impedance Cardiography (ICG)

Role in Hypertension

Problem

- Only 34% of 50 million U.S. hypertensive patients have controlled BP

Hemodynamic Role

- High BP caused by high CO or high SVR
- Anti-hypertensive medications reduce BP by lowering CO or SVR

Challenges

- In spite of new hypertension medications and awareness, treatment success and patient compliance remain low

ICG Role

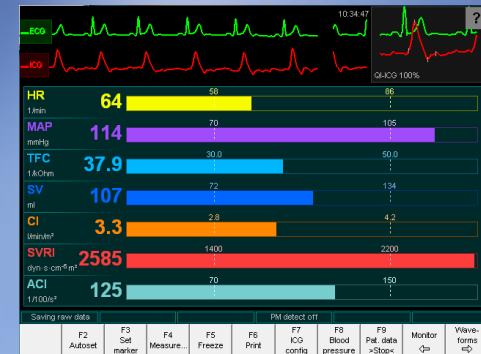
- ICG helps determine cause of high BP in order to target, optimize, and validate medications and assess patient risk

Impedance Cardiography (ICG)

Application in Hypertension

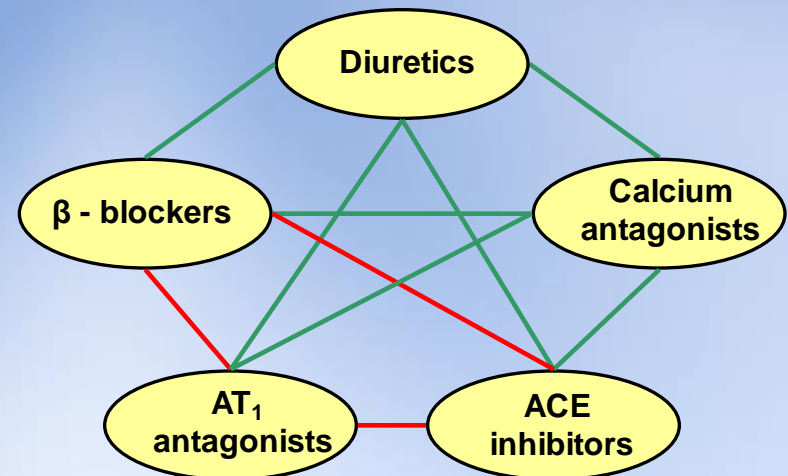
Diagnostic

- Determination of hemodynamic status of patient
- Evaluate cause for hypertension



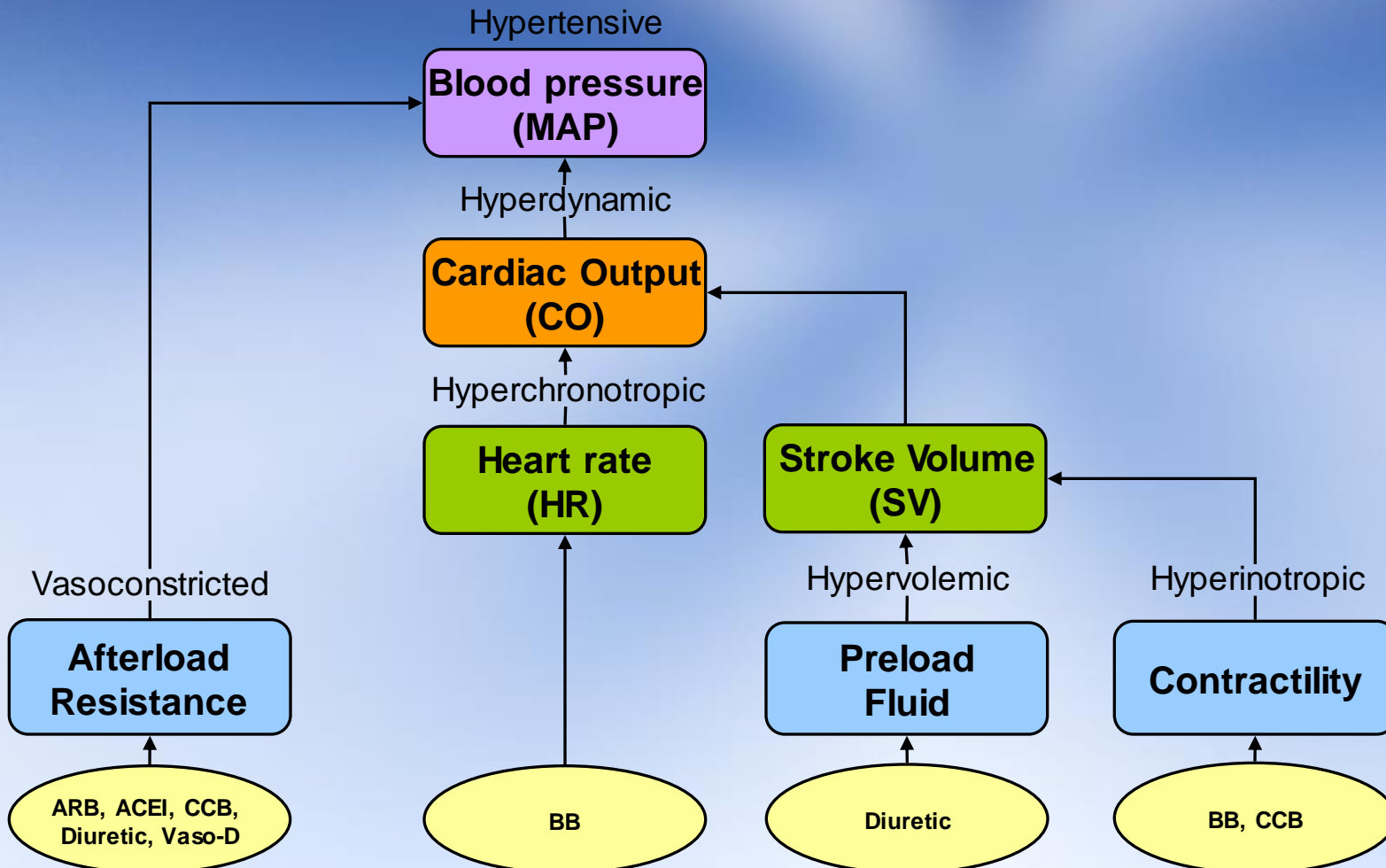
Treatment

- Target and optimize pharmacological therapy based on underlying cause of hypertension
- Identify quantitative fluid changes with TFC parameter
- Detect hemodynamic changes with compliance to medication and diet



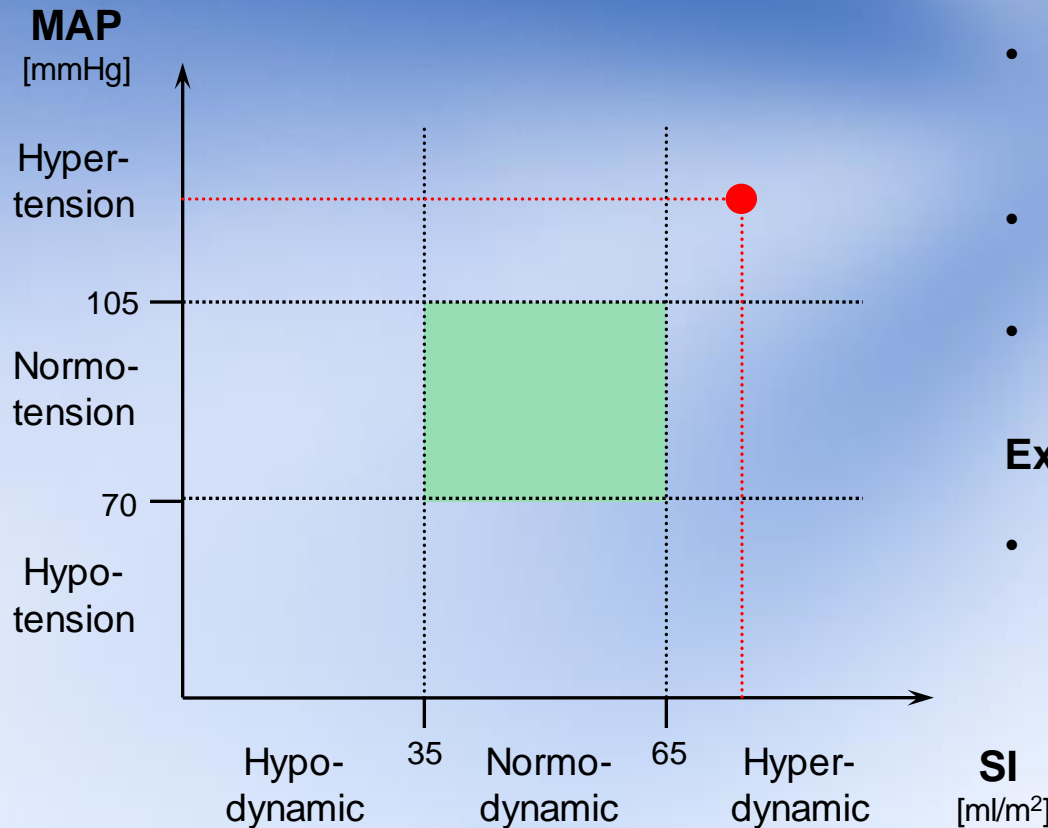
Impedance Cardiography (ICG)

Hemodynamic Components and Implications for Treatment



Impedance Cardiography (ICG)

Therapeutic chart



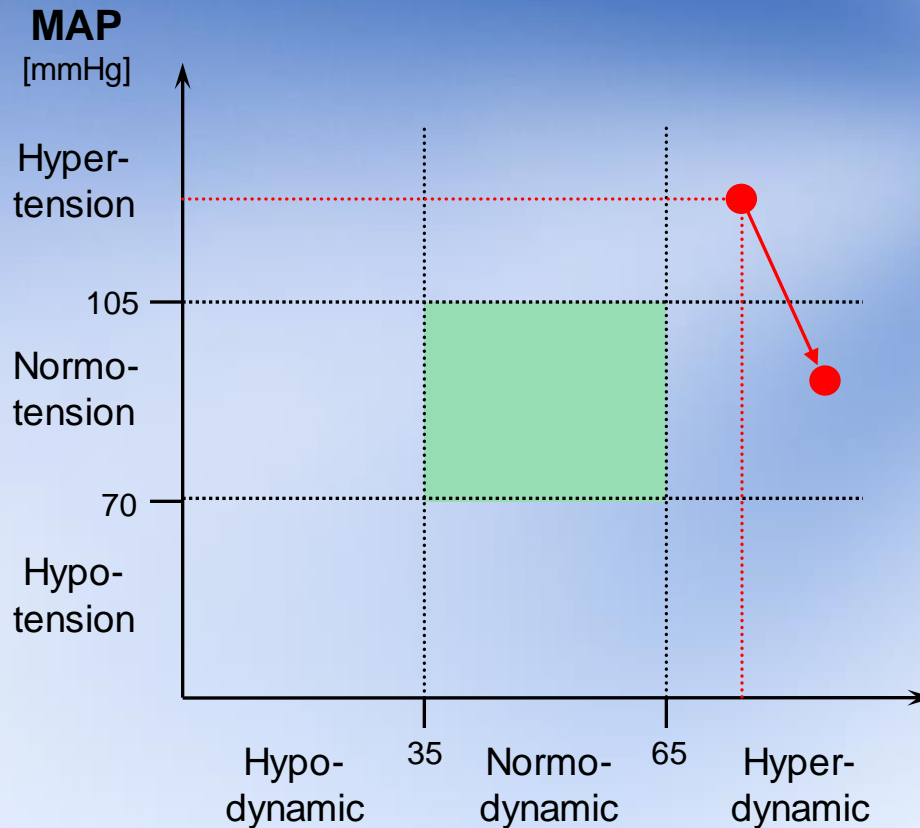
- The Therapeutic chart describes relation of blood pressure and stroke volume
- Goal area describing normohemodynamic state
- Hypertension treatment depending on position in therapeutic chart

Example

- Patient with SI of 75 ml/m² and MAP of 120 mmHg

Impedance Cardiography (ICG)

Therapeutic chart



Example 1

- SI of 75 ml/m² and MAP of 120 mmHg
- Patient is hypertensive and hyperdynamic

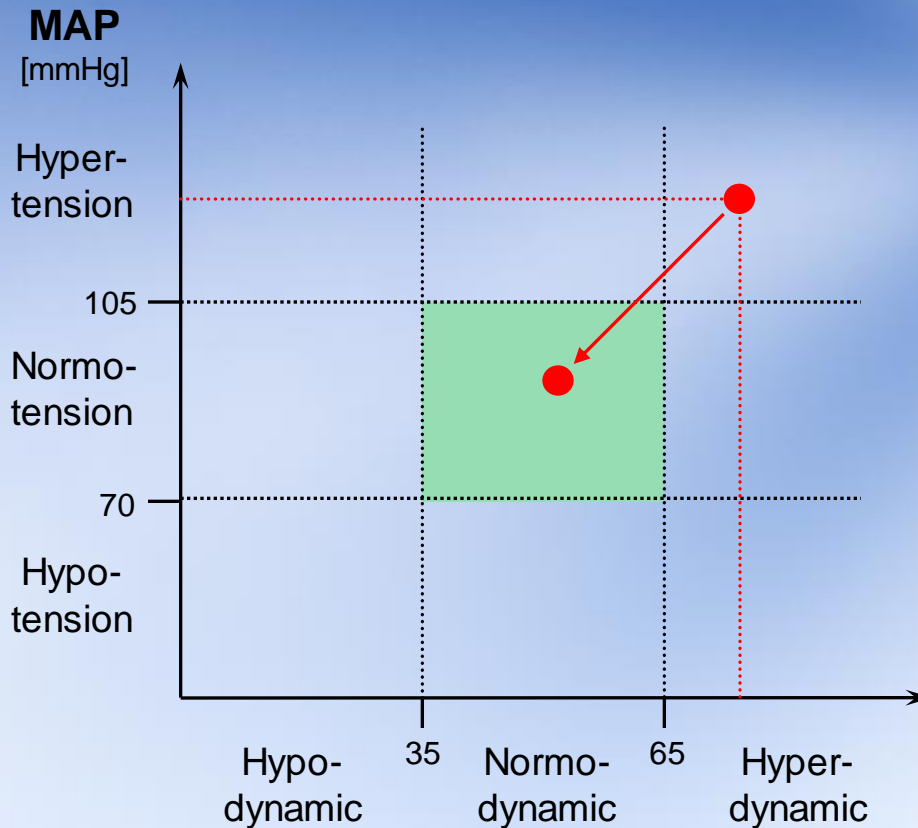
Treatment 1: Vasodillators

- MAP gets normal but patient is still in hyperdynamic state with high workload on the myocardium

► **Bad treatment for this patient**

Impedance Cardiography (ICG)

Therapeutic chart



Example 1

- SI of 75 ml/m² and MAP of 120 mmHg
- Patient is hypertensive and hyperdynamic

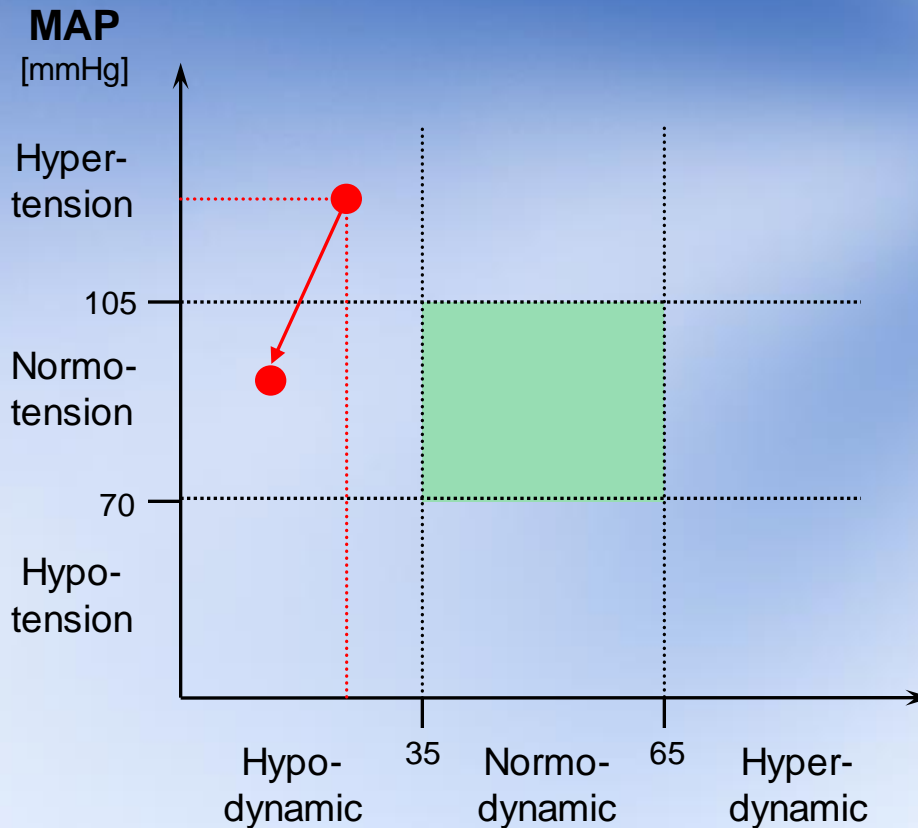
Treatment 2: Negative inotropes

- MAP and SI gets normal and patient status moves to normohaemodynamic

► **Good treatment for this patient**

Impedance Cardiography (ICG)

Therapeutic chart



Example 2

- SI of 25 ml/m² and MAP of 120 mmHg
- Patient is hypertensive and hypodynamic

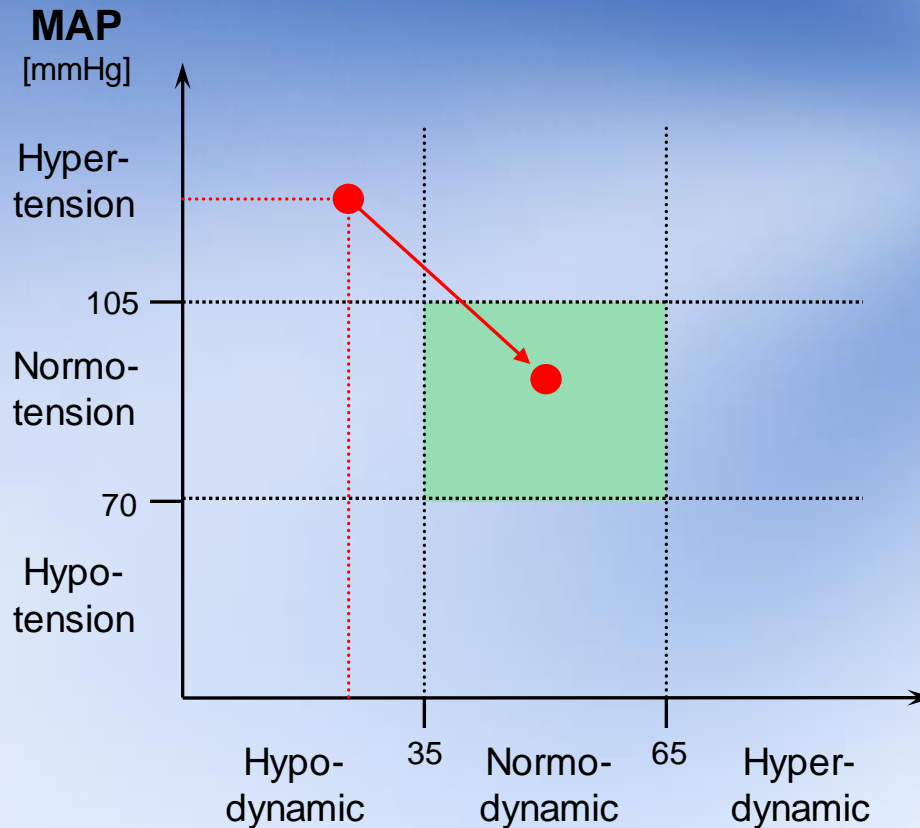
Treatment 1: Diuretics

- MAP gets normal but patient is still in hypodynamic state with low flow

► **Bad treatment for this patient**

Impedance Cardiography (ICG)

Therapeutic chart



Example 2

- SI of 25 ml/m² and MAP of 120 mmHg
- Patient is hypertensive and hypodynamic

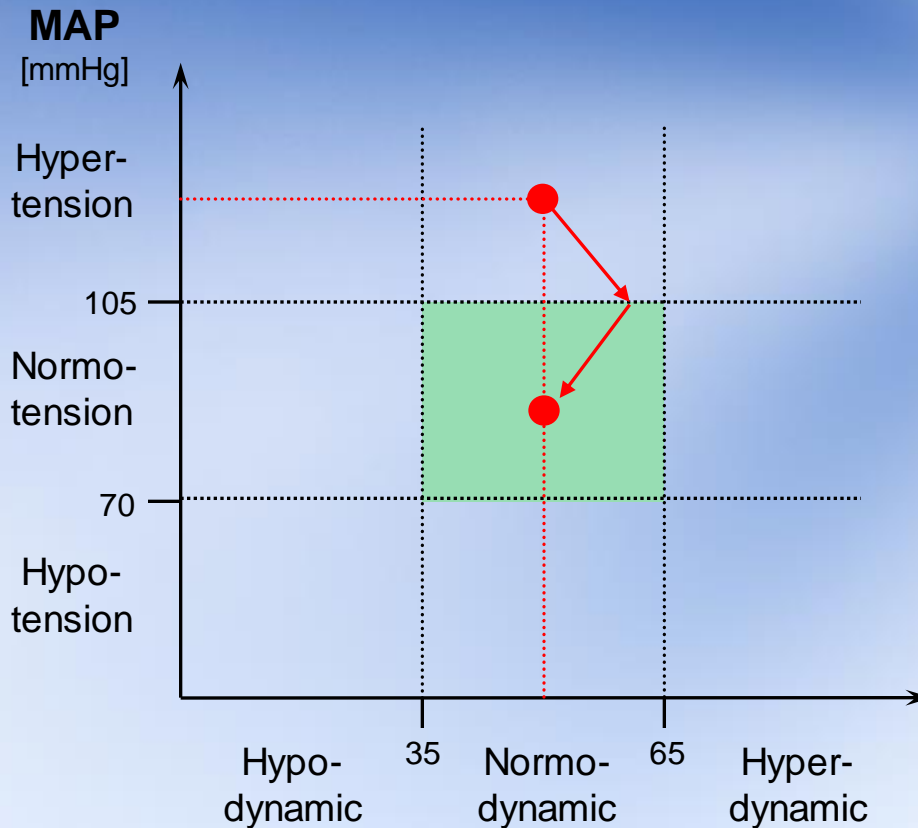
Treatment 2: Vasodilator

- MAP and SI gets normal and patient status moves to normohaemodynamic

► **Good treatment for this patient**

Impedance Cardiography (ICG)

Therapeutic chart



Example 3

- SI of 45 ml/m² and MAP of 120 mmHg
- Patient is hypertensive and normodynamic

Combined Treatment:

Vasodilator + Negative inotropes

- MAP and SI gets normal and patient status moves to normohaemodynamic

Good treatment for this patient

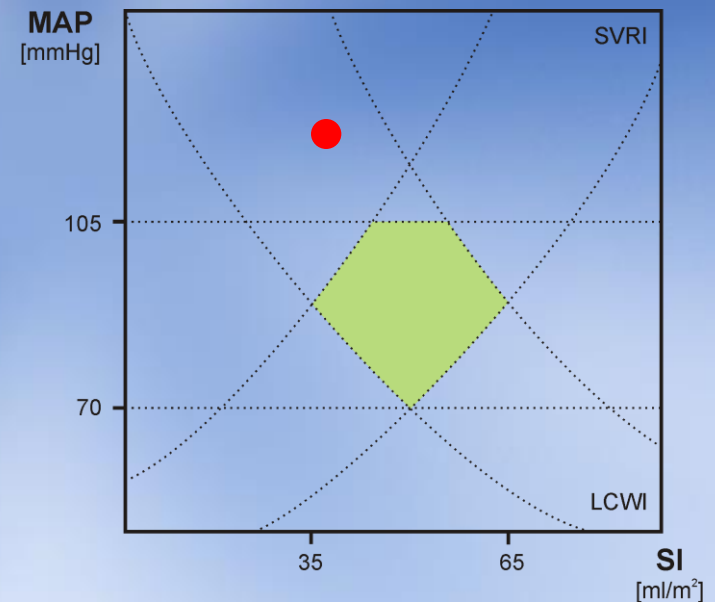
SI
[ml/m²]

Impedance Cardiography (ICG)

Hypertension Case Study

Patient: 41 year old female
History: Hypertension for 1 year
Current therapy: Diuretic (Chlorthalidone 25 mg qd)

Visit	Symptoms/ Exam	CI	SI	SVRI	TFC
#1	No sign or symptoms HR 78, BP 160/100	2.8	36	3257	33.3

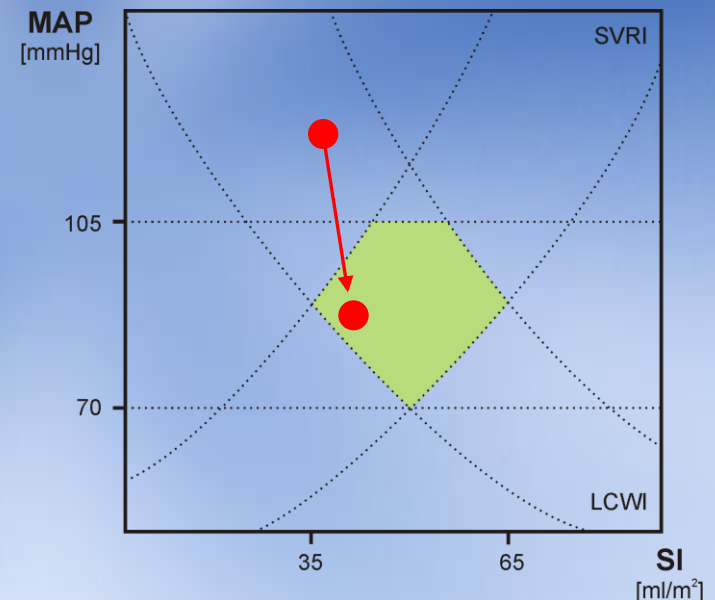


ICG Interpretation: Cause of hypertension is high SVRI
Treatment Decision: Add ACE inhibitor (Lisinopril 5 mg qd)

Impedance Cardiography (ICG)

Hypertension Case Study – cont.

Visit	Symptoms/ Exam	CI	SI	SVRI	TFC
#1	No sign or symptoms HR 78, BP 160/100 (120)	2.8	36	3257	33.3
#2	No sign or symptoms One Week later HR 74, BP 129/60 (83)	2.9	39	2124	32.1



ICG Interpretation: Addition of ACE inhibitor reduced SVRI, lowering BP to acceptable levels.